CEREBELLAR HEMISPHERE

FIBERS which will form the SUPERIOR CEREBELLAR PEDUNCLE

NODULUS

MEDULLA

INTERMEDIATE ZONE

VERMIS

DENTATE NUCLEUS

INTERPOSED NUCLEI (emboliform + globose)

TONSIL

#1186

© 2010 PIXELATED BRAIN

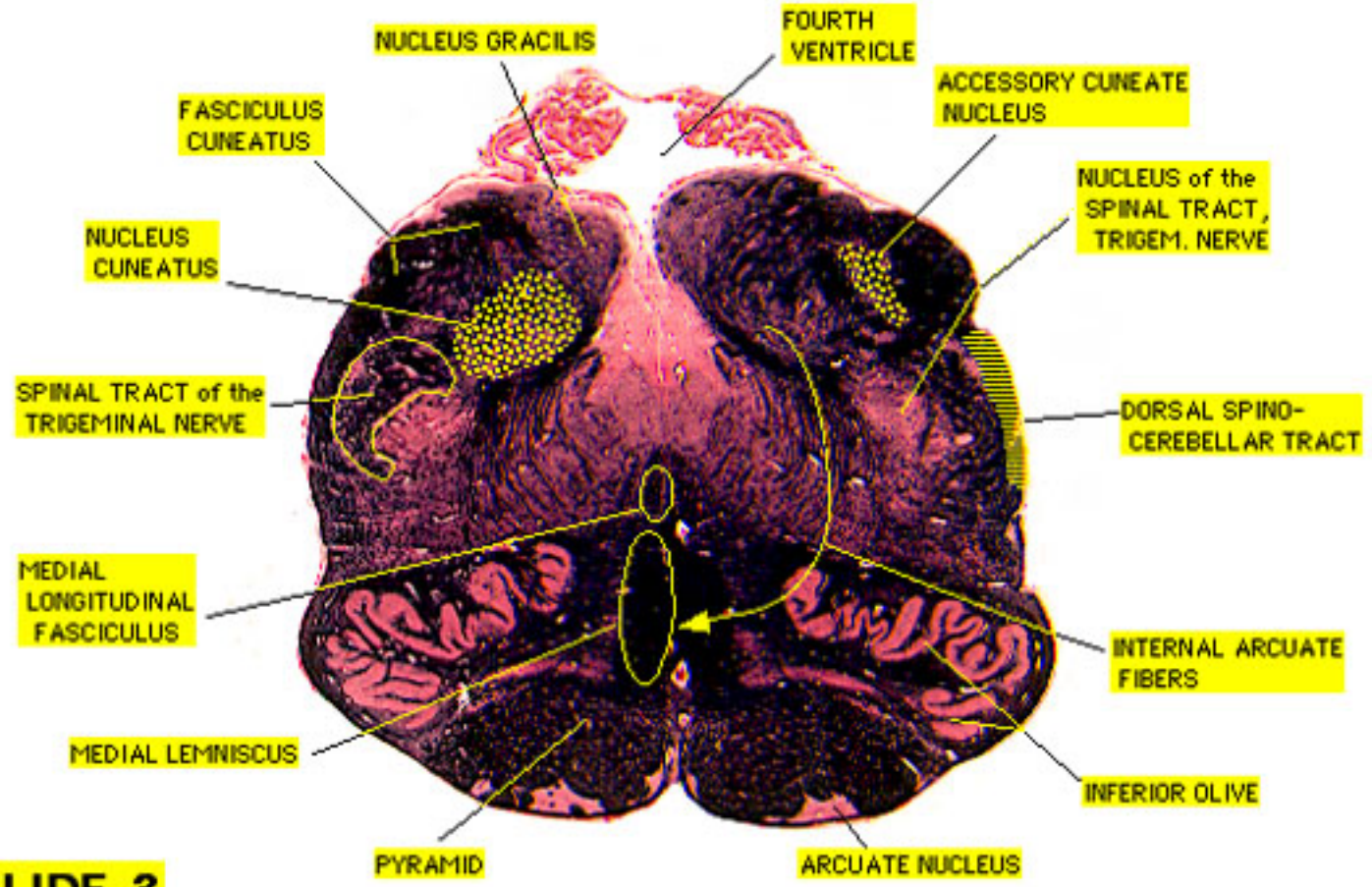


SLIDE 3