THE PIXELATED BRAIN ATLAS

HIPPOCAMPAL COMMISSURE

CORPUS CALLOSUM

PULVINAR

ATRIUM of the LATERAL VENTRICLE

FORNIX (fimbria)

CAUDATE (tail)

HIPPOCAMPUS

DENTATE GYRUS

MIDBRAIN

TECTUM

TENTORIUM CEREBELLI

PONS

TEGMENTUM

CORTICOSPINAL TRACT

INFERIOR HORN of the LATERAL VENTRICLE

CINGULUM

SUBICULUM

TEMPORAL LOBE

PONTO-CEREBELLAR FIBERS

TO PRINT A FREE COPY OF THIS ATLAS, GO TO PIXELATEDBRAIN.COM

© 1998 DCB

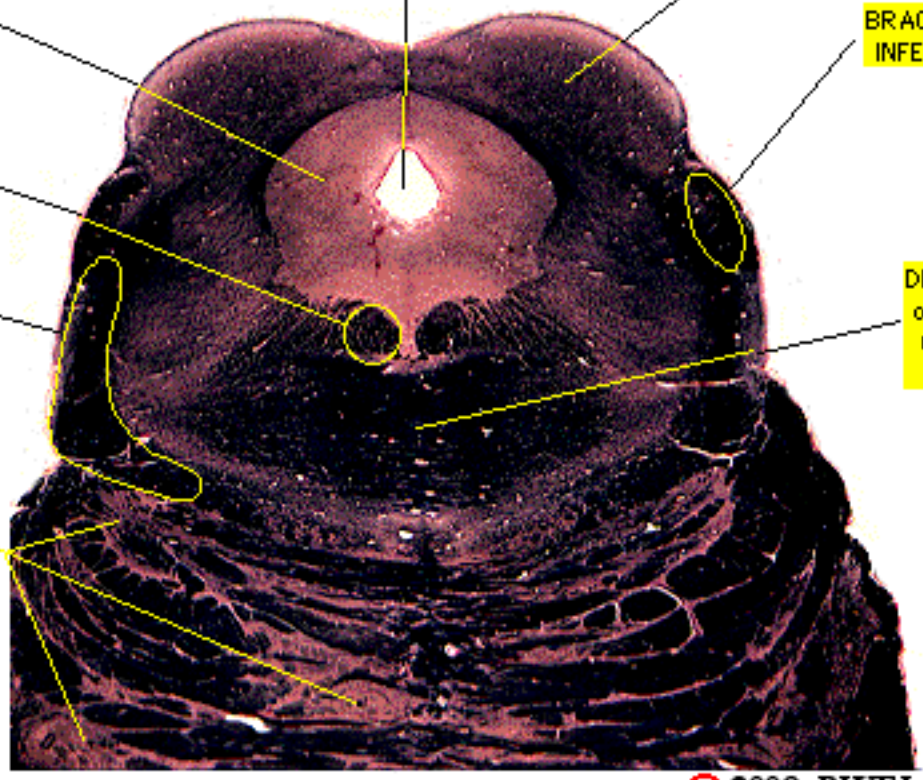

SLIDE 20

© 2009 PIXELATED BRAIN